

TESTICULAR YOLK SAC TUMOR IN AN ONE- YEAR AND SEVENT- MONTHS OLD

Nadirah Rasyid Ridha¹, Farid Huzein², Emir Amal³

Dr. Wahidin Sudirohusodo General Hospital, Makassar ¹, Indonesia Department of
Pediatrics, Hasanuddin University, ^{2,3}

Email: nadirah.bika@gmail.com

ABSTRAK

Latar Belakang: Yolk sac tumor (YST), yang paling sering muncul di gonad sebagai jenis tumor sel germinal, jarang terjadi pada anak-anak tetapi sangat ganas. Tumor testis yang paling umum pada anak di bawah usia 3 tahun adalah tumor kantung kuning telur, dan juga dikenal sebagai karsinoma embrional infantil. **Presentasi Kasus:** Kami menyajikan masa depan klinis YST dalam satu tahun tujuh bulan. Dalam laporan ini, kami menggambarkan testis YST dalam hal manifestasi klinis, pencitraan, dan temuan histopatologi, diagnosis dan pengobatan. Telah disarankan bahwa alpha-fetoprotein (AFP) dapat diterapkan sebagai penanda tumor yang layak karena levelnya meningkat pada > 90% dari YST. Perawatan umumnya melibatkan operasi debulking tumor diikuti dengan kemoterapi sistemik. **Kesimpulan:** Laporan kasus kami memiliki prognosis yang baik karena respon yang baik dengan kemoterapi. Meskipun YST jarang terjadi pada anak-anak, dokter anak harus menyadari hal ini dan pengobatan segera harus ditangani.

Kata kunci: Tumor yolk sac, Kemoterapi, Pediatrik

ABSTRACT

Background: Yolk sac tumor (YST), which most frequently arises in the gonads as a type of germ cell tumor, is rare in children but is highly malignant. The most common testicular tumor in young children under the age of 3 is yolk sac tumor, and it is also known as infantile embryonal carcinoma. Case Presentation: We present the clinical picture of YST in a one-year and seven-month-old child. In this report, we described testicular YST in terms of the clinical manifestation, imaging, and histopathology findings, diagnosis and treatment. It has been suggested that alpha-fetoprotein (AFP) can be applied as a feasible tumor marker because its level was elevated in > 90% of YST. The treatment generally involves debulking surgery of tumors followed by systemic chemotherapy. Conclusion: Our case report has a good prognosis because it responds well to chemotherapy. Although YST is rare in children, pediatric physicians should be aware of this and prompt treatment should be addressed.

Keywords: yolk sac tumor, chemotherapy, pediatric

INTRODUCTION

Yolk sac tumors (YSTs) are primitive germ cell neoplasms derived from the embryonic yolk sac, allantois, or extraembryonic mesenchyme and usually develop in the testes or ovaries. (1) Testicular tumors are rare in children, but highly treatable and usually curable. In children, testicular tumor accounts for ~ 1–2% of all tumors. Among testicular tumors, germ cell tumors have a bimodal age distribution. One peak occurs in the first 2 years of life and the second peak occurs in young adults 15–35 years of age. (2).

YST was universally life-threatening before the development of combination chemotherapy. With the introduction of novel chemotherapeutic regimens in the end of 1970s, the 5-year survival rates of YST significantly improved from 14% to nearly 90%. (Nawa A et al., 2001). Especially adding cisplatin to combination therapies, prognosis of the patients reached excellent values, even for patients with advanced stages. (3). Therefore, YST is rare in children and malignant; however, it could be cured usually. In this report, we described a testicular of YST in an one-year and seven-month-old girl in terms of the

clinical presentation, imaging findings, diagnosis, and treatment.

CASE PRESENTATION

An one-year and seven-months-old boy suffered from testicular pain, enlargement, bleeding since the age of 5 months and getting bigger and painful. On Physical examination on testes; palpable mass size 10 X 8 x 6 cm, unruven surface, solid consistency, well defined, immobile, bleede easily, tenderness, palpable warm. (Figure 1) The multi-slice computed tomography (MSCT) whole abdomen with contrast found isodense mass (20 HU) appears to be post contrast 941 HU), no well-defined, irregular edges, noncalcifications, which fill the bilateral scrotal cavity, appear to originate from bilateral testes, and extend through the suprascrotal through the right tunica vaginalis, impression bilateral testicular masses eith enlargement of the right proximal iliac lymph nodes and right abdominal paraaorta to a level of a right renal. The values of tumor markers, alpha-fetoprotein (AFP), carcinoembryonic antigen (CEA), and beta human chorionic gonadotropin (hCG) were >400 ng/ml, 1,1 ng/ml, and <1.1 ng/ml, respectively. The patient underwent biopsy and result of hystopatology shows dominant hyperemic

necrotizing cells, macro and micro cells, forming a honeycomb image, atypical, pleomorphic, vesicular cells, schiller duval bodies, povesicular vitelline, and hyalin globul. Impression YST.

The definitive diagnosis was YST, then we were treated using the CEBA protocol (cisplatin, etoposide, bleomycin and doxorubicine). After receiving therapy for 2 cycles the tumor shrank with a tumor mass measuring 6 x 4.5 x 5 cm, uneven surface, solid consistency, well defined, immobile, not easy to bleed, painless, warm and hyperemic color. (Figure 2). After receiving therapy for 4 cycles, size tumor 2,5 x 2,5 x 2 cm (Figure 3)

DISCUSSION

A case of testicular YST in a boy 1-year and 7-month of age is reported. The boy suffered from painful testicular mass since 5 months prior to admission. In our hospital, histopathology examination was obtained with result of YST. Testicular YST account for 70–80% of prepubertal malignant testicular tumors and are the most common childhood testicular cancer. (2) Yolk sac tumors are primitive germ cell neoplasms derived from the embryonic yolk sac, allantois, or extraembryonic mesenchyme and usually develop in the testes or ovaries, the

occurrence is rare in childhood, which account for 3.5% of all childhood cancers (15 years). (4) Germinal cell tumor consists of seminoma tumor, teratoma, and nonseminoma. Germ cell tumors account for 60% testicular tumors in children, but 95% of testicular tumors in adults. Adult germ cell tumors such as seminoma and embryonal carcinoma are rare in children. (2) Yolk sac tumor is a malignant non seminomatous tumor with testes being the most common primary site of tumor, around 20% develops from extra-gonadal tissues like mediastinum, sacrocoxygeal region, cervix, vulva(5), pelvis, liver, prostate, and retroperitoneum, with anterior mediastinum being the most common site for extra-gonadal type. (6) It has also been reported that YST occurred in penile shaft, urachus, stomach, liver, lungs, heart, thyroid, nasal region, cranial base, vulva, retroperitoneum, prostate, pericardium, diaphragm, mesentery, mouth, ears, omentum, eyes, and subcutaneous region.(4) The etiology of this tumor is still not completely understood. It is hypothesized that hypermethylation from RUNX3 promotor gene and overexpression of GATA-4, a transcription factor which control differentiation and yolk sac endodermal cell function in its pathogenesis. However

this hypothesis is still yet to be proven. Overall prognosis in children is better as compared to adults. (7) Five-year overall survival rates were 74.1% and 64.0% in patients with EST and embryonal carcinoma, respectively ($p = .57$). Five-year overall survival rates were not different for stage I patients receiving chemotherapy and those not receiving chemotherapy (85.8% versus 100%, $p = .27$). Longterm survival rates were 89.7%, 68.5%, 31.2%, and 30% for stage I, II, III, and IV disease, respectively ($p = .001$). (8)

Three clinical stages for the determination of extension of the tumor have been described. Stage 1 is where the tumor is confined to the testis. Invasion of the epididymis, tunica albuginea, spermatic cord, or scrotum does not change tumor stage, but increases the risk of nodal involvement and the risk of recurrence. In stage 2, the tumor has retroperitoneal lymph node metastasis. Stage 3 is characterized by supraclavicular lymph nodes, visceral involvement, or persistently elevated tumor marker values. The vast majority, 85% of YSTs in children, present as clinical stage 1 disease compared with 35% in adults. (2) Our patient had a stage 3 YST with tumor mass at the testis with retroperitoneal lymph

node and visceral involvement shown in the whole CT abdomen imaging.

Signs and symptoms of YST can vary, expect the common signs and symptoms of malignancy like fever or decrease of body weight, testicular YST may presents with mass at the testes. The most common presentation is of a painless scrotal mass, pain may be associated when torsion of the testes or intra tumoral hemorrhage occurs. Torsion had been reported to occur in about 60% of cases of intraabdominal testicular tumors in prepubertal children. (9) Our patient presented with palpable painful mass that easily bleed, possibly caused by the intra-tumoral haemorrhage (FIGURE1). Other symptoms were unremarkable. Nicholson and Harlan (1995) reported that around one-third of patients with testicular cancer carry genetic predisposition, however our patient had no familial history of malignancy.

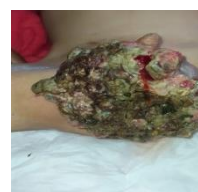

Figure 1: Clinical picture before chemotherapy

There are a number of diagnostic tools applied for YST, such as US, CT, magnetic resonance imaging (MRI),

elevated tumor marker, and histopathological analysis. US characterizes the adnexal mass and shows ascites or hepatic metastasis. CT scan detects carcinosis and adenopathy, MRI reveals the hyper-vascularized and hemorrhagic feature of the mass. US is currently the imaging modality of choice for distinguishing paratesticular from testicular masses. However, it is often non-specific with malignant tumors mimicking the more common benign lesions and vice versa. (7) In our patient, whole abdomen MSCT with contrast was performed, impression of bilateral testicular masses with enlargement of the right proximal iliac lymph nodes and right abdominal paraaorta to a level of a right renal was marked.

Testicular YSTs frequently secrete high concentrations of AFP (2) and it has been suggested that AFP can be applied as a feasible tumor marker because its level was elevated in >90% of YST (4); therefore, AFP is considered important in the diagnosis and follow-up of the tumors. AFP remains the gold standard marker for YSTs, although it can be produced by many non-germ cell tumours, especially in the female genital tract and also in tumours of other organs, usually of endodermal origin frequently with a hepatoid

component. (10) AFP produces strong granular cytoplasmic positivity that may also be present in the hyaline globules, similar with our patient's histopathologic finding with elevated AFP and presence hyaline globule.

Our patient had markedly elevated AFP level (>400 ng/ml), β -human chorionic gonadotropin (β -HCG) 0.1, and carcino embryonic antigen (CEA) was 1.1 ng/ml on initial finding and after 4 cycles on chemotherapy the AFP was 1.1 ng/ml.

The definitive diagnosis for YST is based on histopathologic finding, which demonstrates eosinophilic periodic acid-Schiff (PAS) positive inclusions in the cytoplasm of celar cells that consist of AFP and Schiller-Duval bodies (7). Khan et al reported that tumor cells with solid pattern, reticular, with Schiller-Duval body, globule hyaline, accompanied with extensive necrosis were to be found in YST microscopic examination, which are true to our findings. Examination of the specimen in our patient submitted for histopathology showed dominant hyperemic necrotizing cells, macro and micro cells, forming a honeycomb image, atypical, pleomorphic, vesicular cells, Schiller-Duval bodies, plovesicular vitteline, and hyaline globule, with impression of YST.

Our patient had undergone intravenous chemotherapy for total of 6 cycles using CEBA (cisplatin, etoposide, bleomycin and doxorubicine) protocol. Reduction of tumor sizes were seen after the first 2 cycles of chemotherapy with CEBA protocol (FIGURE 2) and continued to shrunk after 4 cycles. (FIGURE 3 & 4)

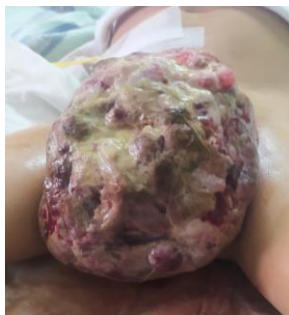

Figure 2: Clinical picture after 2 cycles of chemotherapy

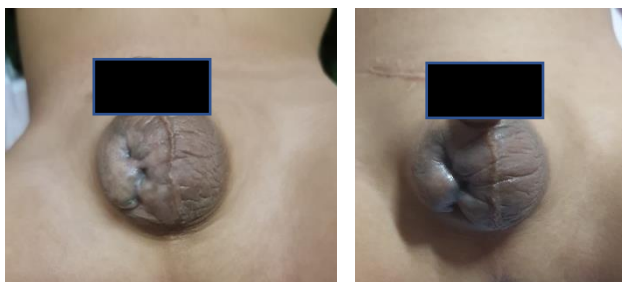


Figure 3 & 4: Clinical picture after 4 cycles of chemotherapy

Thorough observation is needed for the patient in chemotherapy. Although chemotherapy for YSC has produced excellent survival results, its side effects are not negligible. Raynaud's phenomenon (25-30%), ototoxicity (20%), neurotoxicity (15%), and nephrotoxicity (31%) are some

of the common complications that occur in survivors of testicular cancer.(11) Traditionally, 2 years follow-up is recommended for YST patient, includes tumor marker AFP and radiologic examination. If there is no evidence of recurrence after the second year, surveillance using all these methods can be less frequent as the risk is the highest in the first 2 years. (2) Major factors affecting the prognosis are clinical stage, histologic type, and treatment modalities given.

REFERENCE

1. Sakaguchi K, Matsuda K, Suzuki H, Yamamoto N, Kondo Y, Ando T, et al. Testicular yolk sac tumor of myxomatous, reticular, and polyvesicular vitelline type in a newborn calf. *J Vet Diagnostic Investig.* 2013;25(6):811–5.
2. Al-Mendalawi M. Unusual association of testicular yolk sac tumor with pectus excavatum in an 18-month-old child: a case report. *Menoufia Med J.* 2019;32(3):1161.
3. Umezu T, Kajiyama H, Terauchi M, Shibata K, Ino K, Nawa A, et al. Long-term outcome and prognostic factors for yolk sac tumor of the ovary. *Nagoya J Med Sci.*

- 2008;70(1-2):29-34.
4. Chen LH, Yip KC, Wu HJ, Yong SB. Yolk sac tumor in an eight-year-old girl: A case report and literature review. *Front Pediatr*. 2019;7(APR).
 5. Soeselo DA, Suhardi FO, Grimaldy G, Kurniawan F, Widjaja NT, Theresia S, et al. Vulva hygiene awareness to changes in knowledge, attitude and behaviour of teenage students. *Jambura J Heal Sci Res [Internet]*. 2021;3(2):250-5. Available from: <https://ejurnal.ung.ac.id/index.php/jjhsr/article/view/10618>
 6. Risnawati R, Wulandari L. Tumor Mediastinum Anterior (Yolk Sac Tumor) pada Seorang Laki-Laki Dewasa Muda: Sebuah Kasus yang Jarang. *J Respirasi*. 2019;2(2):45.
 7. Lyngdoh TS, Menon P, Jain R, Das A. Primary paratesticular yolk sac tumor: A case report and review of literature. *J Indian Assoc Pediatr Surg*. 2013;18(2):86-9.
 8. Güler E, Kutluk MT, Büyükpamukçu N, Çağlar M, Varan A, Akyüz C, et al. Testicular germ cell tumors in childhood: Treatment results of 52 patients. *Pediatr Hematol Oncol*. 2004;21(1):49-56.
 9. Gupta A, Kureel SN, Bhalla S, Pandey A, Singh G, Rai RK, et al. Yolk sac tumor in intraabdominal undescended testis in a child with normal serum alpha-fetoprotein: a rare case report. *African J Urol*. 2020;26(1):0-4.
 10. Nogales FF, Preda O, Nicolae A. Yolk sac tumours revisited. A review of their many faces and names. *Histopathology*. 2012;60(7):1023-33.
 11. Zhu YP, Zhang SL, Ye DW, Shi GH, Xiao WJ. Yolk sac tumor in a patient with transverse testicular ectopia. *World J Surg Oncol*. 2011;9(Figure 3):2-5.